

Unusual Cause of Bilateral Pleural Effusion

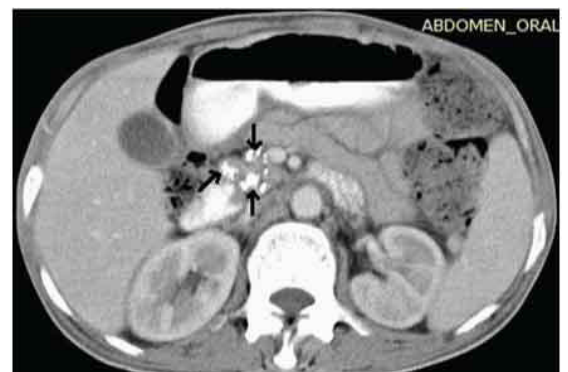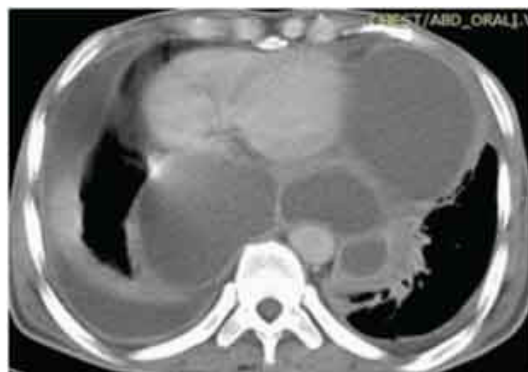
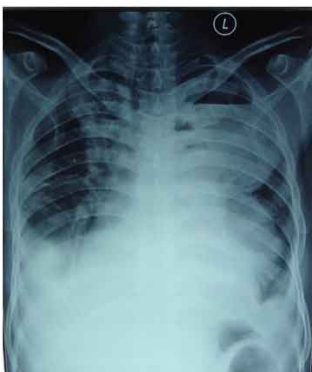K.GOWRINATH¹, P.JYOTHI², C.RAGHAVENDRA³

Keywords: Amylase, Mediastinum, Pseudocyst, Pancreatitis, Pancreaticopleural fistula

A-50-year old male chronic alcoholic and smoker was admitted to our inpatient department of Narayana medical college hospital with pleuritic chest pain, exertional breathlessness and epigastric pain with vomiting of ten days duration. There was history of hypertension and diabetes mellitus for the past three years. Patient stopped drinking alcohol one year back after an episode of acute abdomen. There was history of anti-TB therapy for one month for left sided exudative pleural effusion without much relief. Physical examination findings were not very significant. Chest examination showed bilaterally decreased breath sounds. Urinalysis revealed proteinuria and glycosuria. Routine blood counts were not significant. Blood chemistry showed total bilirubin of 1.87 mg% and random blood sugar of 264 mg%. HIV and viral hepatitis serology were negative. A chest radiograph [Table/Fig-1] showed left sided cyst like opacities and bilateral pleural effusion. An abdominal ultrasound revealed enlarged pancreas. Cardiac work up was negative. A computed tomographic (CT) scan of chest [Table/Fig-2] revealed bilateral pleural effusion, intercommunicating cystic lesions in the left pleural cavity and posterior mediastinal pseudocysts. Serum level of amylase was 942 U/L (normal <220 U/L), lipase was 185 U/L (normal 13-60 U/L) and protein was 6.5 g/dl. At pleural tap, pleural fluid was brownish and had protein level of 3.7 g/dl, lactose dehydrogenase (LDH) level of 1050 U/L (normal <220 U/L) and 70% lymphocytes. Pleural fluid adenosine deaminase (ADA) level was 40U/L (normal <40 U/L) and amylase level was 3392 U/L (normal <220 U/L). All other pleural fluid reports were negative. Upper abdominal section of contrast enhanced CT scan [Table/Fig-3] showed a pseudocyst around the enlarged pancreas with calcifications in the head and body regions (Black arrows). Initial therapeutic pleural aspiration on left side was followed by rapid reaccumulation of pleural fluid within four days and tube thoracostomy was done. Patient responded well to treatment with cefoperazone plus salbactam, parenteral nutrition and pleural drainage. Check radiograph of chest [Table/Fig-4] showed complete lung expansion on left side but check CT [Table/Fig-5] showed persistence of mediastinal pseudocysts. A diagnosis of bilateral pleural effusion with thoraco-abdominal pancreatic pseudocysts

complicating chronic pancreatitis was made and the patient was referred to surgical gastroenterologist for further management.

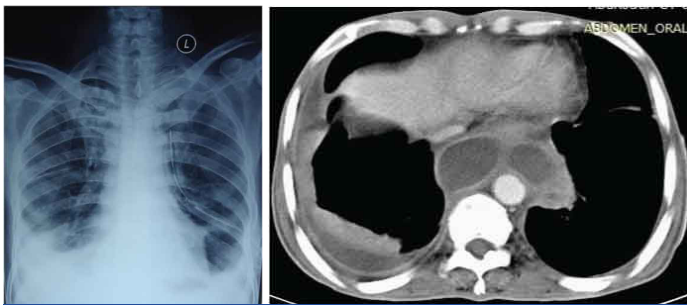
Massive recurrent pleural effusion in chronic calcifying pancreatitis and pseudocyst is rare [1]. Mediastinal pseudocysts with recurrent bilateral pleural effusion in chronic pancreatitis are very rare [2]. Pancreatitis may cause pleural effusion if inflammation spreads directly into thoracic cavity through the diaphragm or extends into mediastinum through diaphragmatic openings or if pancreaticopleural fistula (PPF) develops between the ruptured pancreatic duct or pseudocyst and the pleural cavity [3]. A posterior mediastinal pseudocyst results if pancreatic duct ruptures posteriorly spilling pancreatic secretions into retroperitoneal area which may reach mediastinum via oesophageal or aortic hiatus. In our case, right pleural effusion was smaller and further decreased with medical treatment suggesting that it resulted from direct spread of pancreatic inflammation via diaphragmatic lymphatics [4] and the pleural effusion on left side was massive and recurrent with markedly raised pleural fluid amylase in the setting of chronic calcifying pancreatitis was virtually diagnostic of PPF [5]. To the best of our knowledge, this is the first case reporting in the literature of this type. Endoscopic retrograde cholangiopancreatography (ERCP) or magnetic resonance cholangiopancreatography (MRCP) are other diagnostic techniques [6] and they help to view the pancreatic ductal anatomy and morphology before planning further management. In our case, CT scan could not demonstrate any fistulous track of PPF and further diagnostic tests like ERCP or MRCP were not done. There is no standardized treatment protocol for PPF. Recently, an algorithm for optimal management of PPF was suggested [7] which limits medical treatment for PPF with normal or mildly dilated pancreatic duct, ERCP stent for partial ductal stenosis and surgery if ductal obstruction is complete or located in the tail or proximal to the fistula. Surgery is the definite treatment whenever medical or endoscopic therapy fails. Spontaneous resolution of mediastinal pseudocyst is rare and its treatment options include long term careful observation for spontaneous regression, medical management, internal or external drainage with endoscopic,



[Table/Fig-1]: Chest radiograph (PA view) showing cyst like opacities on left side and bilateral pleural effusion

[Table/Fig-2]: CT scan of chest showing multiple thoracic pseudocysts and bilateral pleural effusion

[Table/Fig-3]: A section of contrast enhanced CT scan showing a pseudocyst around enlarged pancreas with calcifications in the head and body regions (Black arrows)



[Table/Fig-4]: Chest radiograph of chest showing chest tube in-situ with complete expansion of left lung and pleural effusion on right side

[Table/Fig-5]: A section of CT scan of chest showing posterior mediastinal pseudocysts

percutaneous or open surgical approach [8]. In our case, one week tube thoracostomy drainage and parenteral nutrition were effective but mediastinal pseudocysts did not regress. With a view to limit complications and recurrence rate, we referred the case for early operative intervention which had 94% success rate compared to 31% who received medical treatment [9].

REFERENCES

- [1] Kumar S, Diwan SK, Dekate M. Chronic pancreatitis presenting as recurrent pleural effusion. *Online J Health Allied Scs.* 2013;12:1-2.
- [2] Lee DH, Shin DH, Kim TH, Park SS, Park KN, Lee JH. Mediastinal pancreatic pseudocyst with recurrent pleural effusion. Demonstration by endoscopic retrograde cholangiopancreatogram and subsequent computed tomography scan. *J Clin Gastroenterol.* 1992;14(1):68-71.
- [3] Mackowiak PA, Sellier P, Monsuez JJ, Fadel E, Evans J, Vittecoq D. An unusual case of haemorrhagic left pleural effusion. *Clin Infect Dis.* 2006;42(10):1496-97.
- [4] Miller JA, Maldjian P, Seeff J. Pancreaticopleural fistula, an unusual course of persistent unilateral pleural effusion. *Clin Imaging.* 1998;22(2):105-07.
- [5] Aswani Y, Hira P. Pancreaticopleural fistula: A review. *JOP, J Pancreas (Online).* 2015;16: 90-4.
- [6] Machado NO. Pancreaticopleural fistula: Revisited. *Diag Ther Endosc.* 2012, Article ID815476. 5 pages, 2012. doi:10.1155/2012/815476.
- [7] Wronski M, Slodkowski M, Cebuski W, Moronczyk D, Krasnodebeski IW. Optimizing management of Pancreaticopleural fistulas. *World J Gastroenterol.* 2011;17(42):4696-703.
- [8] Ajmera AV, Judge TA. Mediastinal extension of pancreatic pseudocyst- a case with report of topic and management guidelines. *Am J Ther.* 2012;19(5):e152-56.
- [9] King JC, Reber HA, Shiraga S, Hines OJ. Pancreatic-pleural fistula is best managed by early operative intervention. *Surgery.* 2011;147:154-59.

PARTICULARS OF CONTRIBUTORS:

1. Professor, Department of Pulmonary Medicine, Narayana Medical College, Nellore, Andhra Pradesh, India.
2. Senior Resident, Department of Pulmonary Medicine, Narayana Medical College, Nellore, Andhra Pradesh, India.
3. Postgraduate, Department of Pulmonary Medicine, Narayana Medical College, Nellore, Andhra Pradesh, India.

NAME, ADDRESS, E-MAIL ID OF THE CORRESPONDING AUTHOR:

Dr. K. Gowrinath,
Flat No.103, Bhavani Park Centraapartments, Children's Park Road, 9th Street,
Ramjinaragar, Nellore-524002, Andhra Pradesh, India.
E-mail : drgowrinathk@hotmail.com

FINANCIAL OR OTHER COMPETING INTERESTS: None.

Date of Submission: **Dec 19, 2014**
Date of Peer Review: **Apr 12, 2015**
Date of Acceptance: **May 13, 2015**
Date of Publishing: **Jun 01, 2015**